

# The Impact of Cataract Surgery on Preexisting Retinal Disease

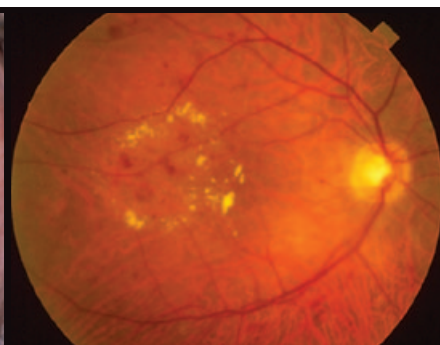
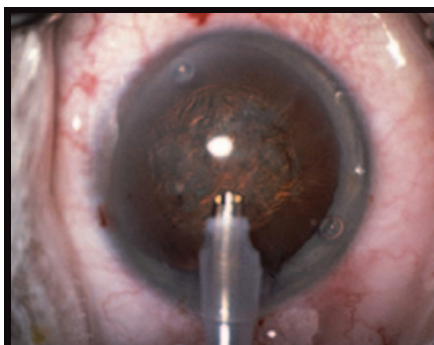
BY SAMER E. FARAH, MD

EDITED BY SHARON FEKRAT, MD, AND INGRID U. SCOTT, MD, MPH

In the past two decades, there have been tremendous advances in cataract surgery. Better technology and greater proficiency allow safer and faster surgery, with better visual outcomes and shorter recovery times. And a more active and optically demanding aging population has led to the increased need for cataract surgery. One population-based study of the elderly in the United States found a dramatic linear increase in the rate of cataract surgery in the past 25 years.

Despite this good news about cataract surgery, there is a growing awareness of the effect of cataract surgery on a range of preexisting retinal pathology, and the decision to perform cataract surgery in eyes with preexisting retinal disease is often challenging. Arguing for the removal of cataracts is the obvious fact that their presence can dramatically impair the patient's vision and, for the physician, can hinder the visualization and management of underlying retinal pathology. Likewise, the ability to use optical coherence tomography for evaluating retinal thickness—a mainstay in today's management of many retinal diseases—can be markedly hindered by certain types of cataract. But cataract surgery can exacerbate retinal disease, and, ironically, some treatments for retinal disease, like intravitreal corticosteroids and pars plana vitrectomy, can themselves cause cataracts.

This article will review recent evidence on the relationship between



**GROWING DEBATE.** There have been a number of recent articles examining the effect of cataract extraction on retinal diseases like AMD and diabetic retinopathy.

cataract surgery and some of the most common retinal diseases, namely, age-related macular degeneration, diabetic retinopathy, retinal vein occlusion (RVO), epiretinal membrane and vitreomacular traction, and it will discuss some perioperative measures that can enhance surgical outcomes.

## Effect on Visual Acuity

The good news is that two recent, large studies have shown that visual acuity improves after cataract surgery both in patients with AMD and in those with diabetic retinopathy. The Age-Related Eye Disease Study (AREDS) report No. 27 found that patients with AMD of varying severity had a statistically significant gain in visual acuity that was maintained for an average of 1.4 years after cataract surgery. That report also showed no difference in visual acuity outcomes among eyes with either geographic atrophy or choroidal neovascularization or both. Similarly, the Early Treatment Diabetic Retinopathy

Study report No. 25 showed that most patients with mild to severe nonproliferative or early proliferative diabetic retinopathy and/or macular edema experienced visual improvement one year after cataract surgery.

## Diabetic Retinopathy

Despite these two reports, there is growing evidence that diabetic retinopathy progresses more rapidly after cataract surgery, even after phacoemulsification cataract surgery. One recent Australian study conducted between 2004 and 2006 found that phacoemulsification cataract surgery doubled the progression rate of diabetic retinopathy in the 12 months after surgery.<sup>1</sup> The incidence rate of new diabetic retinopathy in those who did not have retinopathy before surgery was 28 percent in operated eyes as opposed to 14 percent in unoperated eyes (adjusted odds ratio of 2.65). The rate of progression of preexisting retinopathy accelerated as well (36 percent as

opposed to 20 percent, adjusted odds ratio of 2.21). As would have been expected, this was a better outcome, with less progression, than was documented previously with intracapsular and extracapsular cataract surgical techniques.

### Age-Related Macular Degeneration

The effect of cataract surgery on the course of AMD is more controversial, and the results of the different studies are inconsistent. Multiple epidemiological studies suggest that cataract surgery accelerates the progression of AMD. Many of these population-based studies are, however, reports of prevalence, and it is hard to differentiate between association and causation. The effect of cataract surgery on AMD gets further confused when one looks at early as opposed to late disease and wet as opposed to dry AMD and considers the standards used to evaluate and grade the macular degeneration. In addition, there is inconsistency in the risk factors being controlled statistically. For instance, the Beaver Dam Eye Study reported an association between cataract surgery and early AMD; Freeman and colleagues found an association between cataract surgery and late AMD<sup>2</sup>; the Blue Mountains Eye Study did not find an association between cataract surgery and either early or late AMD; and the Rotterdam Study found an association between cataract surgery and early AMD but not wet AMD.

A recent prospective uncontrolled study of 71 patients with non-neovascular AMD found that, at 12 months after phacoemulsification cataract surgery, the rate of progression to neovascular AMD in this cohort was not higher than what would have been expected without the surgery.<sup>3</sup>

Another study looked at the 10-year incidence of AMD and its association with both cataract and cataract surgery.<sup>4</sup> The investigators found that cataract at baseline was associated with early AMD, but not with late AMD. At 10 years after cataract surgery, there was an increased incidence of late AMD. These findings are interesting

because of the temporal relationship between the events, and the long-term follow-up at 10 years. The authors conclude that cataract surgery increased the risk for late AMD.

### Retinal Vein Occlusion

With an estimated prevalence of 1–2 percent in some population-based studies, retinal vein occlusion is the second most common retinal vascular disease after diabetic retinopathy. Many of these patients are elderly and have cataracts, and a common treatment of RVO, an intravitreal corticosteroid, increases the risk that a cataract will develop and progress. Patients with an RVO who then undergo cataract surgery have an increased risk of postoperative cystoid macular edema (CME). In one large study by Henderson and colleagues conducted between 2001 and 2006, the risk of postsurgical CME in uncomplicated cataract surgery was 30 times higher if the operated eye had a history of RVO.<sup>5</sup> This risk persisted even in eyes without preoperative macular edema.

### Epiretinal Membrane and Vitreomacular Traction

The risk of post-cataract surgery CME is also increased in patients with epiretinal membrane.<sup>5</sup> Because of the forward movement of the vitreous after the lens is removed, as well as vitreous liquefaction, vitreomacular traction can be exacerbated in these patients.

### Possible Mediating Factors

Besides the movement of the vitreous created by the loss of lens volume after cataract surgery, changes in postoperative levels of the intraocular angiogenic factors and other cytokines may play a role in the potential effect of cataract surgery on preexisting retinal disease. One study in diabetic patients from Japan found that a high aqueous humor level of VEGF at the time of phacoemulsification cataract surgery correlated with an increased risk of postoperative macular edema.<sup>6</sup> A small study from London in patients with diabetic retinopathy showed

that aqueous levels of VEGF-165 increased one day after uncomplicated phacoemulsification cataract surgery from a median baseline of 68 pg/ml preoperatively to 723 pg/ml one day postoperatively.<sup>7</sup> There was a similar rise in interleukin-1 beta and pigment epithelium–derived factor.

### Risk Factors and Recommendations

A history of hypertension in diabetic patients, the presence of undertreated diabetic retinopathy or an inadequate response to treatment has a negative effect on postoperative retinal edema, progression of retinopathy and visual outcome. On the other hand, patients with an HbA1c of 7.5 percent or less, and those who have more intensive photocoagulation of their diabetic retinopathy, do better.<sup>6,8,9</sup>

**NSAIDs.** Topical nonsteroidal anti-inflammatory drops may prevent the development of CME and progression of macular edema in some patients with diabetic retinopathy or RVO. Some authors recommend starting NSAIDs a few days before cataract surgery, with continued use of both NSAIDs and corticosteroid drops for three months after the surgery.<sup>5</sup>

**Anti-VEGF treatment.** The perioperative use of 1.25 mg of intravitreal bevacizumab has been shown to reduce post-cataract surgery retinal edema as well as the progression of diabetic retinopathy, at least in the short term. One has to be cautious, however, since VEGF is not the only factor causing the development of diabetic macular edema, and there have been reports of recurrent macular edema despite significantly lower concentrations of VEGF after a single intravitreal injection of bevacizumab.<sup>10</sup> Moreover, intravitreal bevacizumab should be used cautiously in eyes with proliferative diabetic retinopathy, since it may lead to rapid regression of neovascularization and traction retinal detachment.

**Nutritional supplements.** In patients with AMD, the AREDS report No. 27 showed that the AREDS nutritional supplement did not affect visual acuity outcomes in patients who had cataract surgery. Improved visual acu-

ity was seen in the group receiving either the AREDS supplement or placebo 1.4 years after surgery. The long-term benefits of the AREDS supplement in patients with AMD are, however, well established, and it is recommended that those who fit the criteria of the AREDS study for risk of AMD progression take these supplements and continue to do so after surgery.

**Ultraviolet light.** UVL and sun exposure are commonly thought to be risk factors for AMD. Surgeons should consider a choice of a UVL-blocking IOL in patients with AMD who are undergoing cataract surgery. It is also important to advise patients to get UVL protection by wearing glasses and hats on sunny days postoperatively.

In conclusion, cataract surgery improves vision in patients with retinal disease and is necessary in order for the physician to monitor and treat the underlying pathology. Some consideration, however, should be given to the possible impact of the surgery on the progression of underlying retinal disease, and additional perioperative measures might be helpful in optimizing the results.

---

*Dr. Farah is assistant professor of ophthalmology and visual sciences at Albert Einstein College of Medicine, New York, and he reports no financial interests.*

---

1 Hong, T. et al. *Ophthalmology* 2009;116(8):1510–1514.

2 Freeman, E. E. et al. *Am J Ophthalmol* 2003;135(6):849–856.

3 Dong, L. M. et al. *Arch Ophthalmol* 2009;127(11):1412–1419.

4 Klein, R. et al. *Arch Ophthalmol* 2002;120(11):1551–1558.

5 Henderson, B. et al. *J Cataract Refract Surg* 2007;33:1550–1558.

6 Funatsu, H. et al. *J Cataract Refract Surg* 2002;28(8):1355.

7 Patel, J. I. et al. *Br J Ophthalmol* 2006;90(6):697–701.

8 Parness, R. et al. *Harefuah* 2005;144(11):763–767.

9 Murtha, T. and J. Cavallerano. *Curr Opin Ophthalmol* 2007;18(1):13–18.

10 Roh, M. I. et al. *Ophthalmology* 2009;166(1):80–86.



# Orbital Gala

OUR CONTINUING QUEST FOR EXCELLENCE IN EDUCATION


*Come Celebrate in Chicago!*

**Sunday, Oct. 17, 6 p.m.**

**Palmer House Hilton**

*Dinner, dancing and silent auction*

*Black tie optional*



Join us in celebrating the 30th anniversary of the Foundation of the American Academy of Ophthalmology and its ongoing mission to support the Academy's priority programs and projects, including education, quality of care research and public service.

While you're at the 2010 Joint Meeting, enjoy a special evening at the historic Palmer House Hilton – one of Chicago's most iconic, treasured landmarks. Don't miss this wonderful opportunity to connect with friends and Academy leaders to benefit the mission of the Academy and its Foundation.

To learn more or purchase tickets, visit [www.faaao.org](http://www.faaao.org).

